Neuropsychiatric symptoms in adults with Tuberous Sclerosis Complex (TSC)

Andy Liu, M.D., M.S.
Adult Neurologist
Duke University School of medicine
Department of Neurology

Department of Neurology
Duke University School of Medicine

Outline

- Physical manifestations
- Medical and Surgical advancements in TSC
- Tuberous sclerosis Associated Neuropsychiatric Disorder (TAND)
- Age related disorders
- Understand the relationship between TAND and age related disorders

Outline

- Physical manifestations
- Medical and Surgical advancements in TSC
- Tuberous sclerosis Associated Neuropsychiatric Disorder (TAND)
- Age related disorders
- Understand the relationship between TAND and age related disorders

Physical traits of TSC throughout life

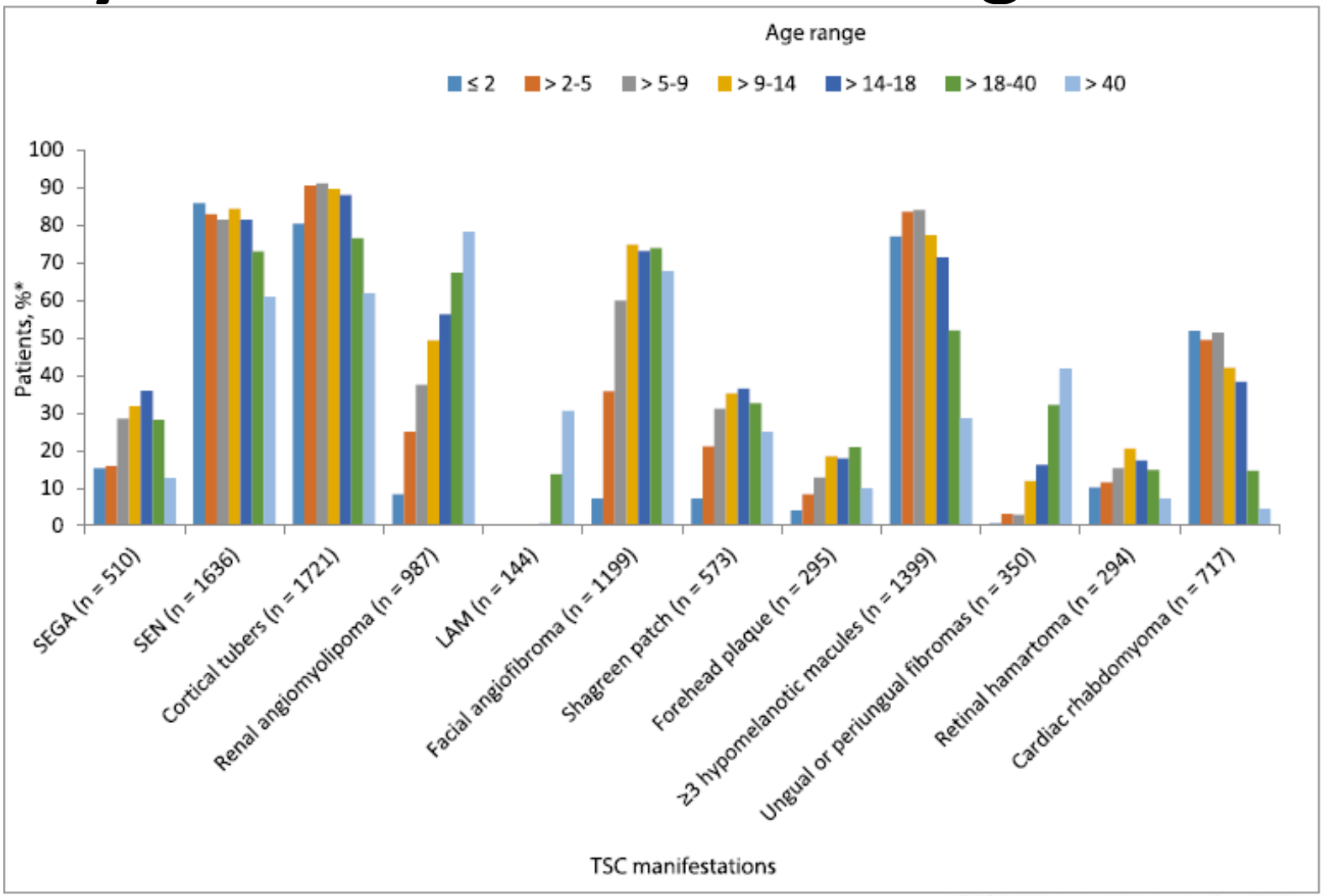

Kingwood et al. 2017

Department of Neurology
Duke University School of Medicine

Outline

- Physical manifestations
- Medical and Surgical advancements in TSC
- Tuberous sclerosis Associated Neuropsychiatric Disorder (TAND)
- Age related disorders
- Understand the relationship between TAND and age related disorders

Medical advancement: EXIST-3 trial

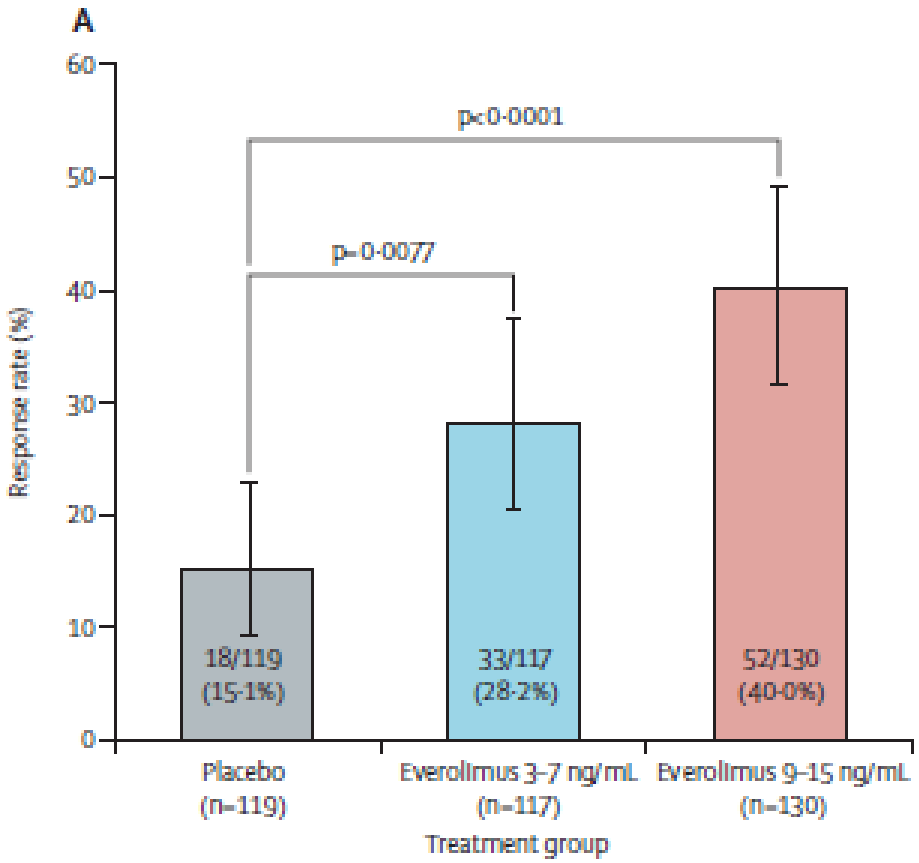

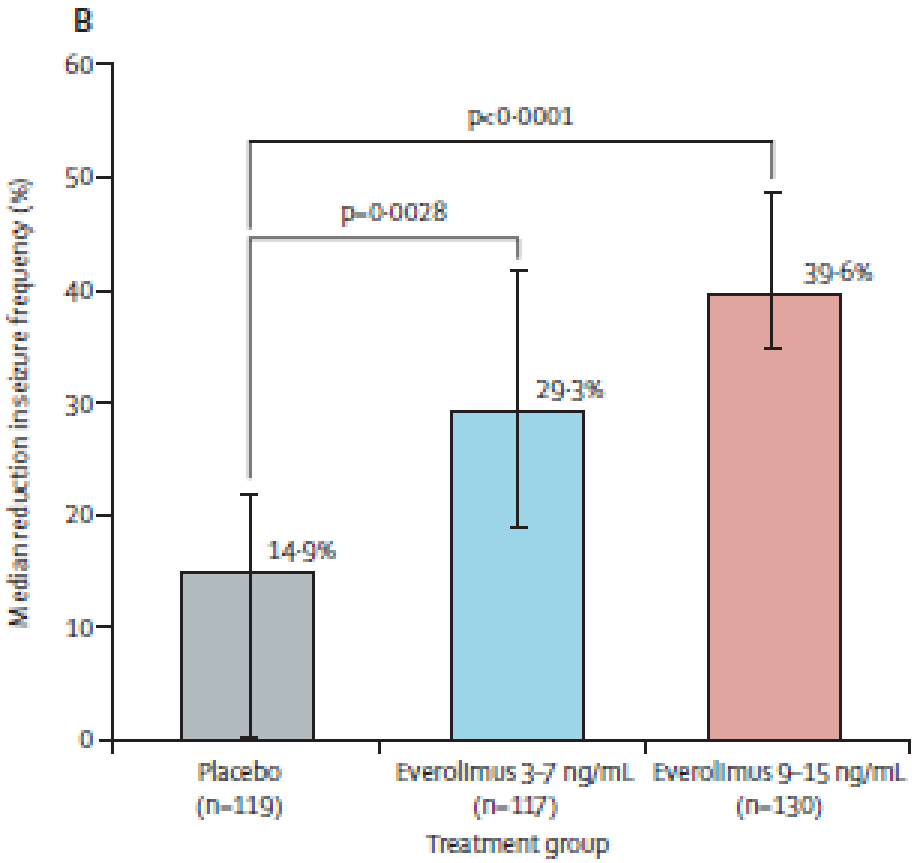

French et al. 2016

Department of Neurology
Duke University School of Medicine

Medical and Surgical advancement

Magnetic Resonance Imaging (MRI) FLAIR

Positron Emission Tomography (PET)

MRI T1

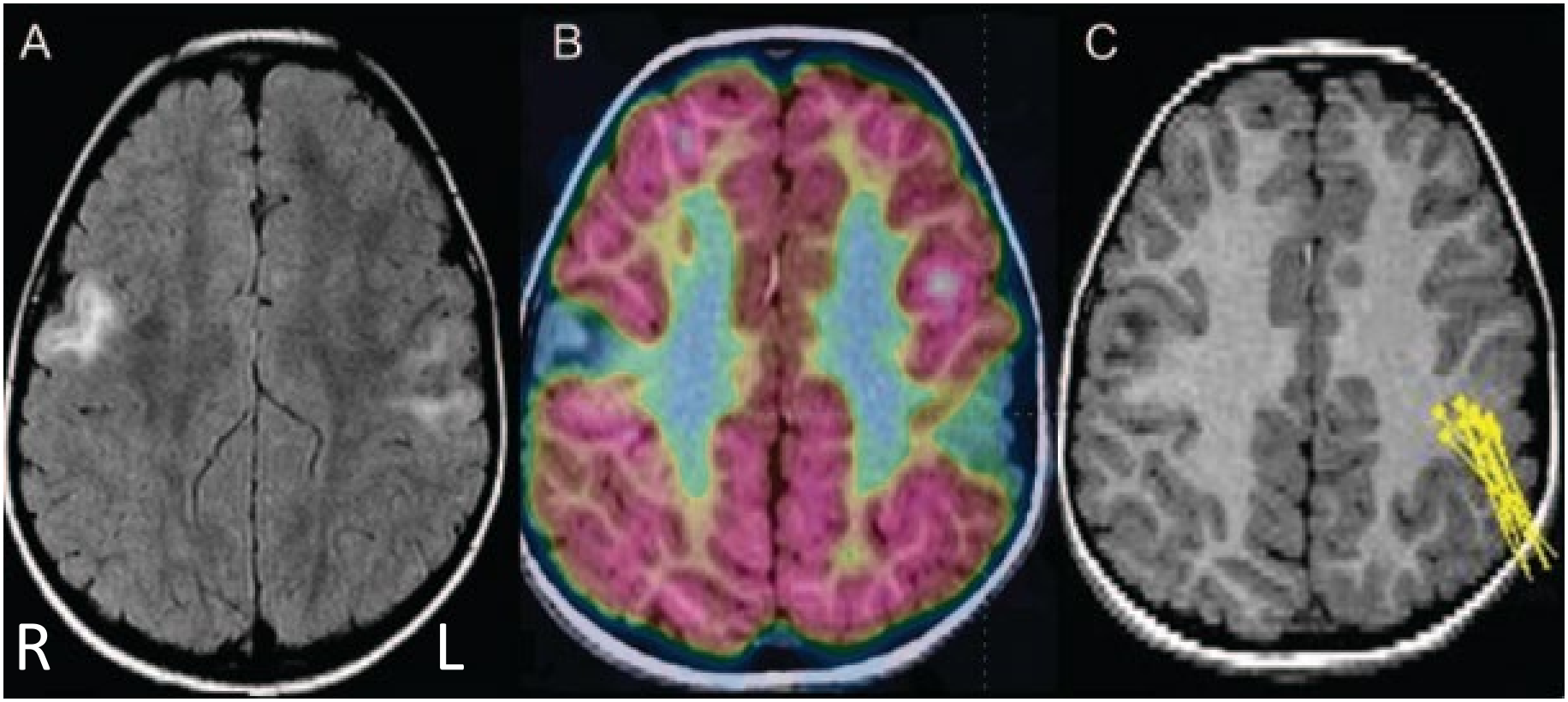

Wu et al 2010

Outline

- Physical manifestations
- Medical and Surgical advancements in TSC
- Tuberous sclerosis Associated Neuropsychiatric Disorder (TAND)
- Age related disorders
- Understand the relationship between TAND and age related disorders

TAND

Cognitive	Behavioral	Psychiatric
Memory	Aggressive outbursts	Depressed mood
Visuospatial function	Temper tantrums	Anxiety
Attention	Self-injury	Mood swings
Multi-tasking	Repeating words	Obsessive compulsive disorder
Planning	Difficulty getting along	Psychotic disorder
Organizing	Inflexible	
Language difficulties	Over/hyperactive	

DeVries et al. 2015

TAND

Cognitive	Behavioral	Psychiatric
Memory	Aggressive outbursts	Depressed mood
Visuospatial function	Temper tantrums	Anxiety
Attention	Self-injury	Mood swings
Multi-tasking	Repeating words	Obsessive compulsive behaviors
Planning	Difficulty getting along	Psychotic disorder
Organizing	Inflexible	
Language difficulties	Over/hyperactive	

DeVries et al. 2015

Outline

- Physical manifestations
- Medical and Surgical advancements in TSC
- Tuberous sclerosis Associated Neuropsychiatric Disorder (TAND)
- Age related disorders
- Understand the relationship between TAND and age related disorders

Frontotemporal Dementia (FTD)

- Early-onset age related disorder with 3 subtypes
- Behavioral variant Frontotemporal Dementia
- Semantic variant Primary Progressive Aphasia
- Nonfluent variant Primary Progressive Aphasia

Olney et al 2017

MRI T1: *TSC1* mutation and FTD

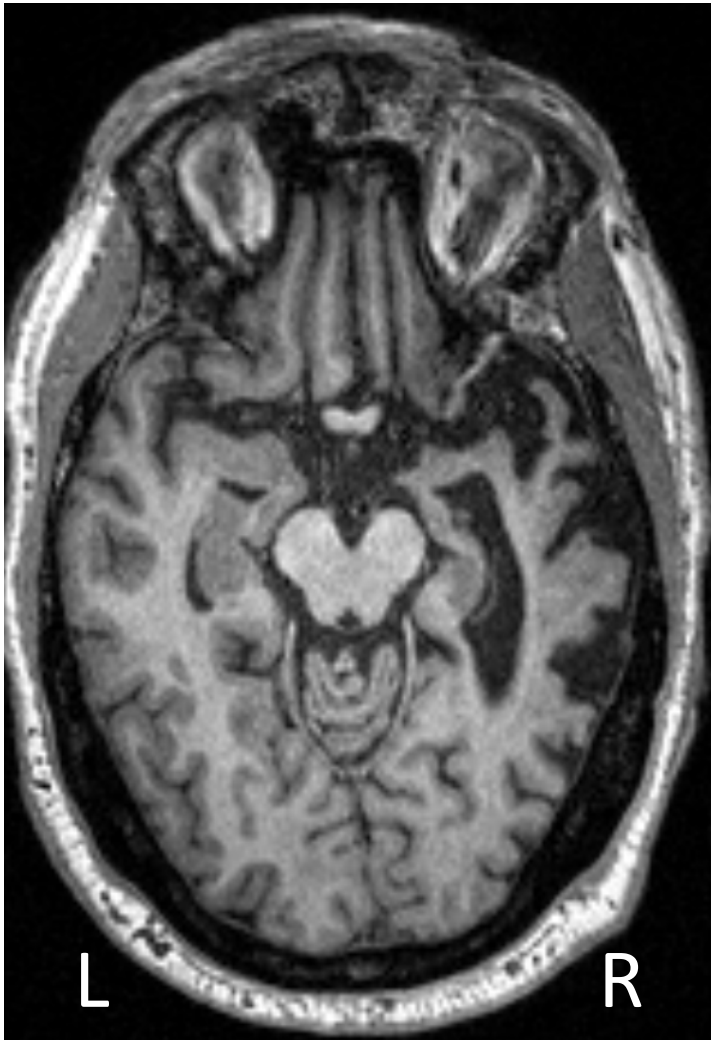

Olney et al 2017

Department of Neurology
Duke University School of Medicine

MRI FLAIR: *TSC1* mutation and FTD

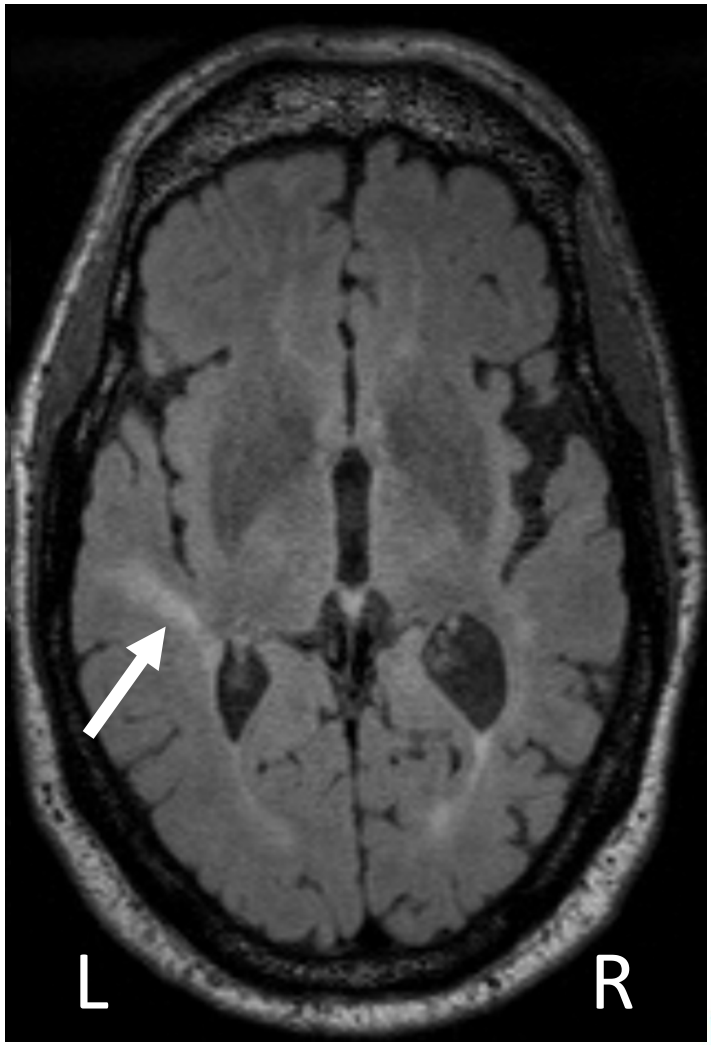

Olney et al 2017

Department of Neurology
Duke University School of Medicine

MRI T1: *TSC1* mutation and FTD

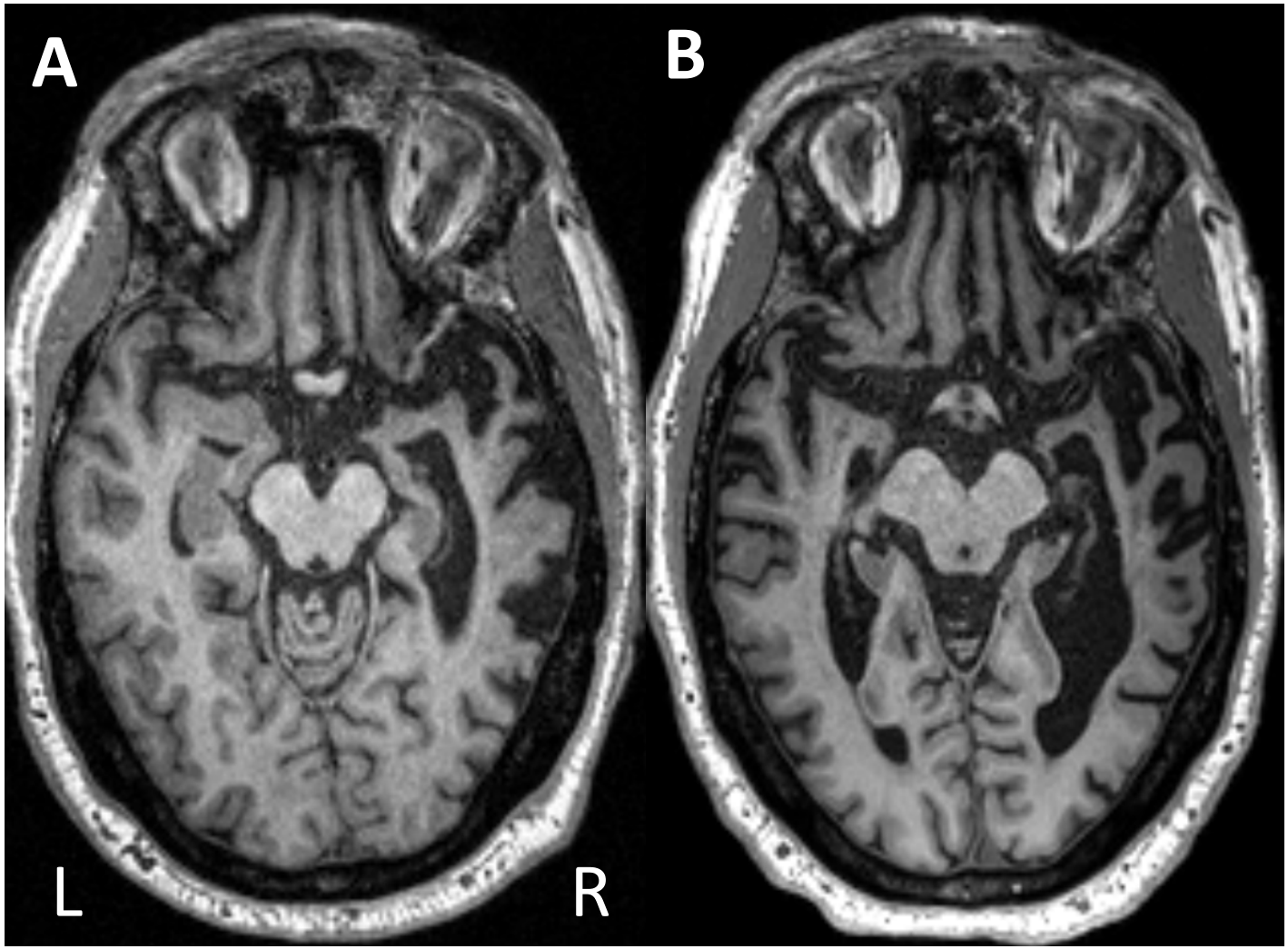

Liu et al 2019 (accepted)

Outline

- Physical manifestations
- Medical and Surgical advancements in TSC
- Tuberous sclerosis Associated Neuropsychiatric Disorder (TAND)
- Age related disorders
- Understand the relationship between TAND and age related disorders

UCSF TSC study 2017-2019

Inclusion Criteria

- Over age 18
- Can complete neuropsychological testing

Exclusion Criteria

- Other genetic diseases

Clinical evaluation

3 groups

- TSC
- FTD
- Normal cognition

Clinical testing

- TAND checklist
- Neuropsychological testing

Objective analysis

Imaging

- MRI brain
- PET scan

Cerebral spinal fluid (CSF)

- Phosphorylated Tau (p-tau)
- Neurofilament light (NfL)
- Amyloid beta 42 (Aβ42)
- Total Tau (t-tau)

Results

- 18 TSC participants were evaluated
- Age ranged from 27-66
- 72% were female
- Genetic testing was finalized in 10 participants
- Equal number of *TSC1* and *TSC2* mutations were identified

TAND checklist

- Behavioral and cognitive domains
- Psychiatric domain

Liu et al 2019 (accepted)

Neuropsychological testing results

- Executive and language domains
- Memory
- Visuospatial domain

Liu et al 2019 (accepted)

Flortaucipir (FTP) PET results

- 3 TSC participants
- Focal uptake of FTP in all participant
- Focal uptake of FTP was seen in the structural changes of the brain in 2 of out 3 participants

Liu et al 2019 (accepted)

MRI T1

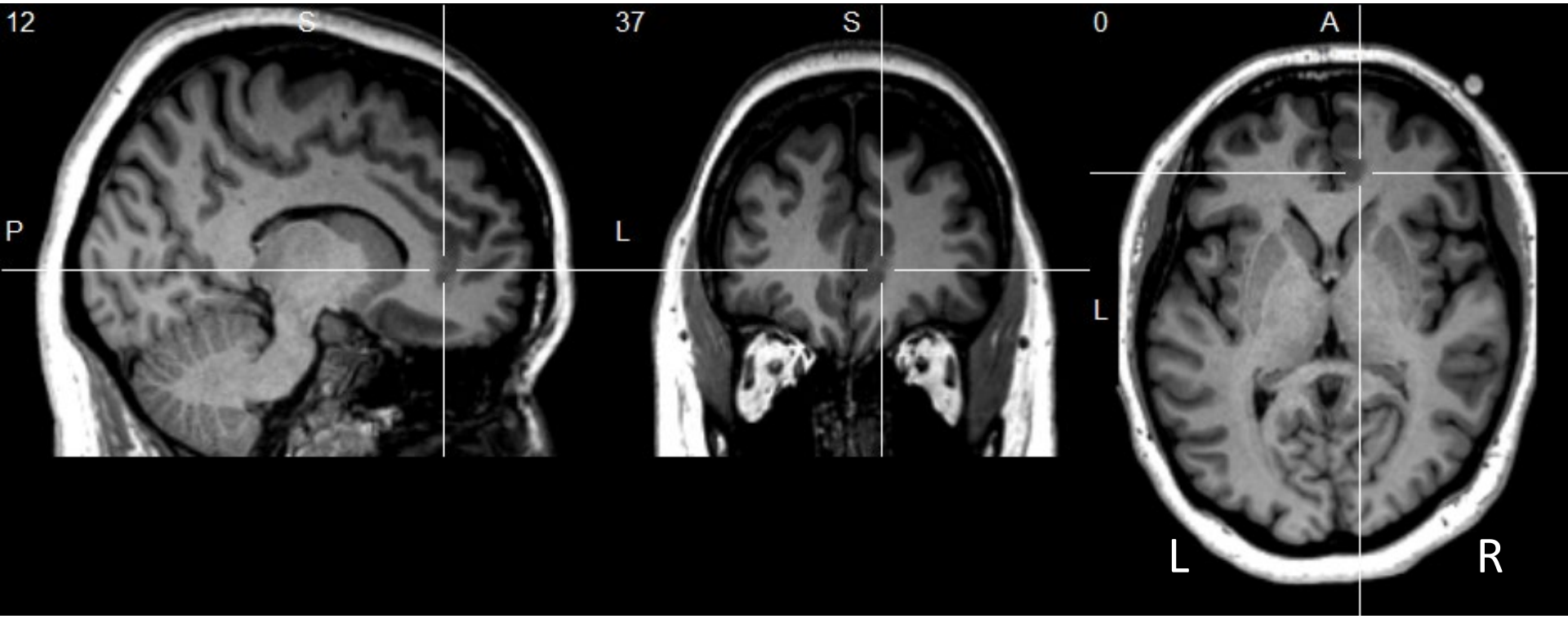

Liu et al 2019 (accepted)

Department of Neurology
Duke University School of Medicine

MRI FLAIR

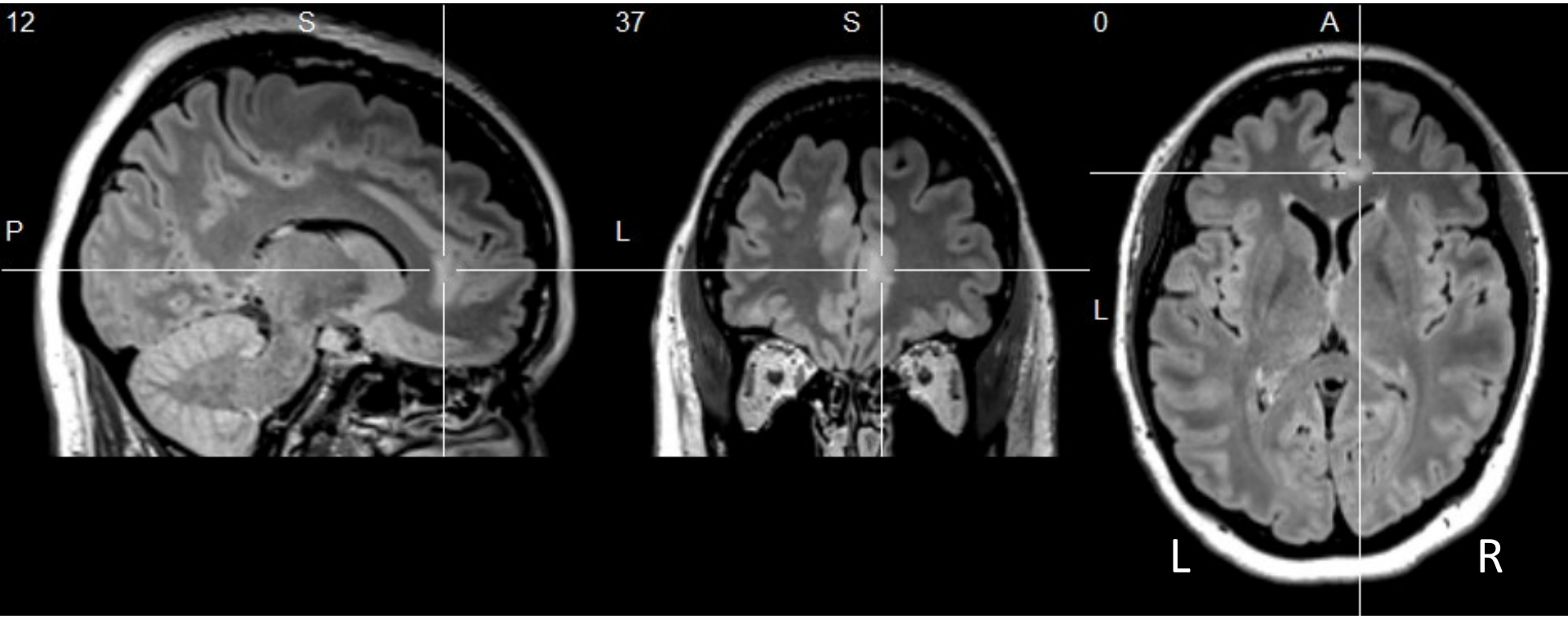

Liu et al 2019 (accepted)

FTP-PET

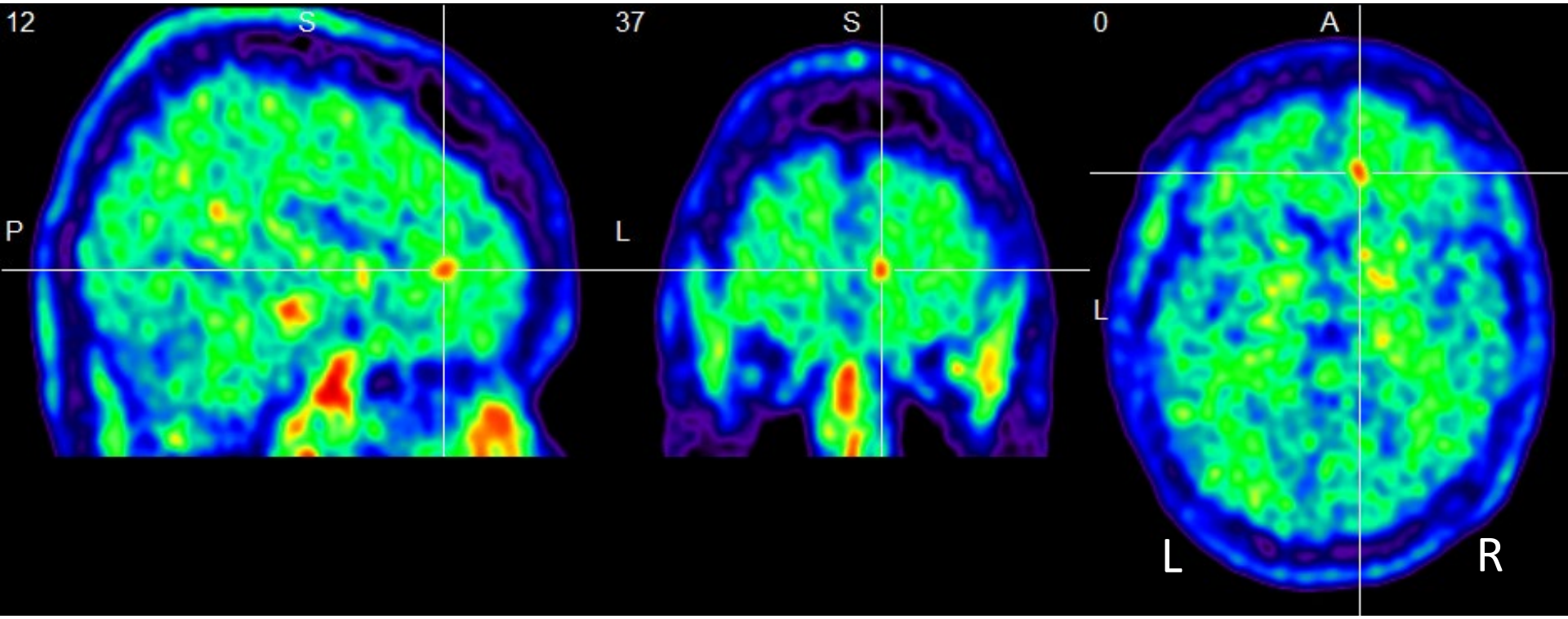

Liu et al 2019 (accepted)

Department of Neurology
Duke University School of Medicine

MRI and PET images

T1

FLAIR

FTP-PET

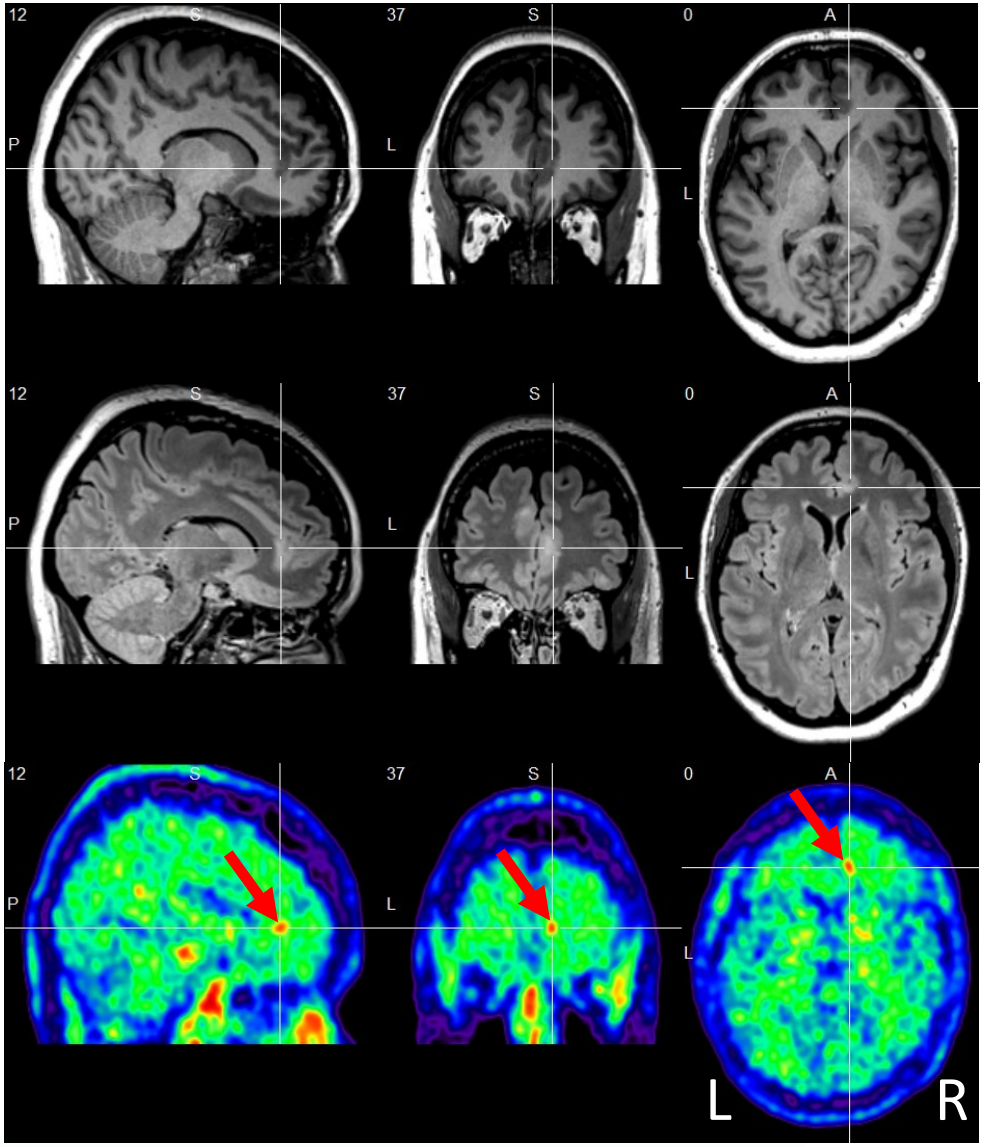

CSF results

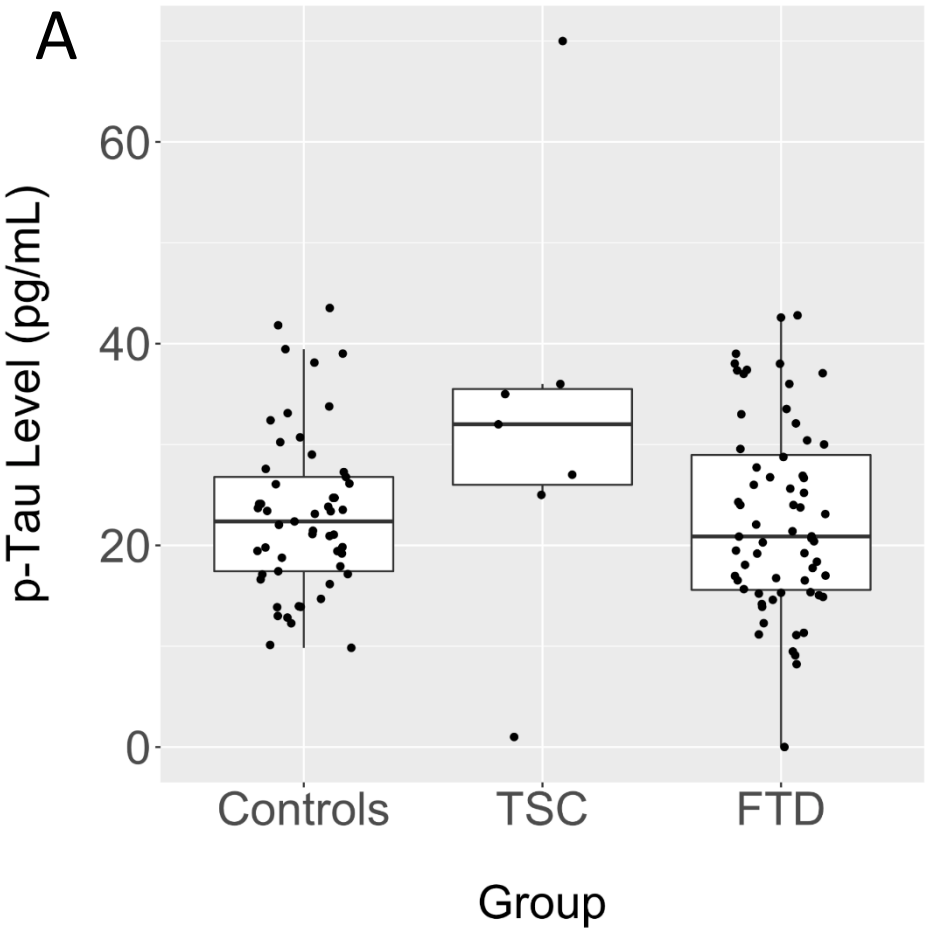

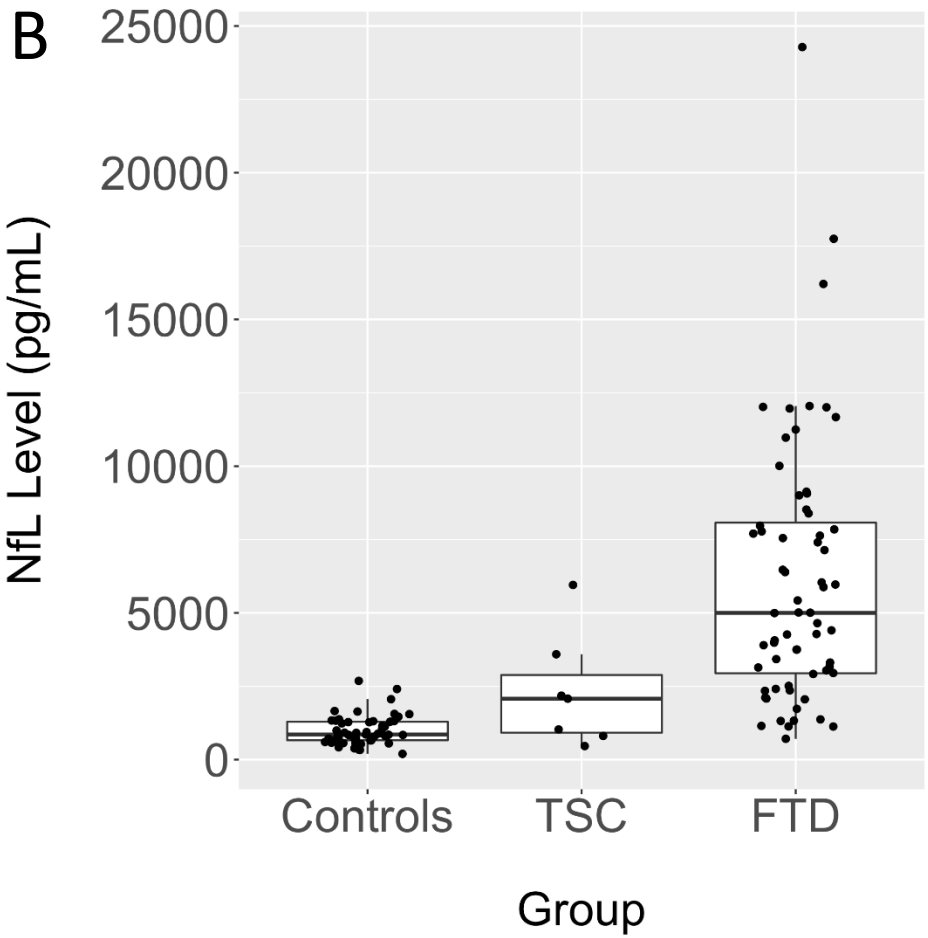

Liu et al 2019 (accepted)

Department of Neurology
Duke University School of Medicine

CSF results (cont)

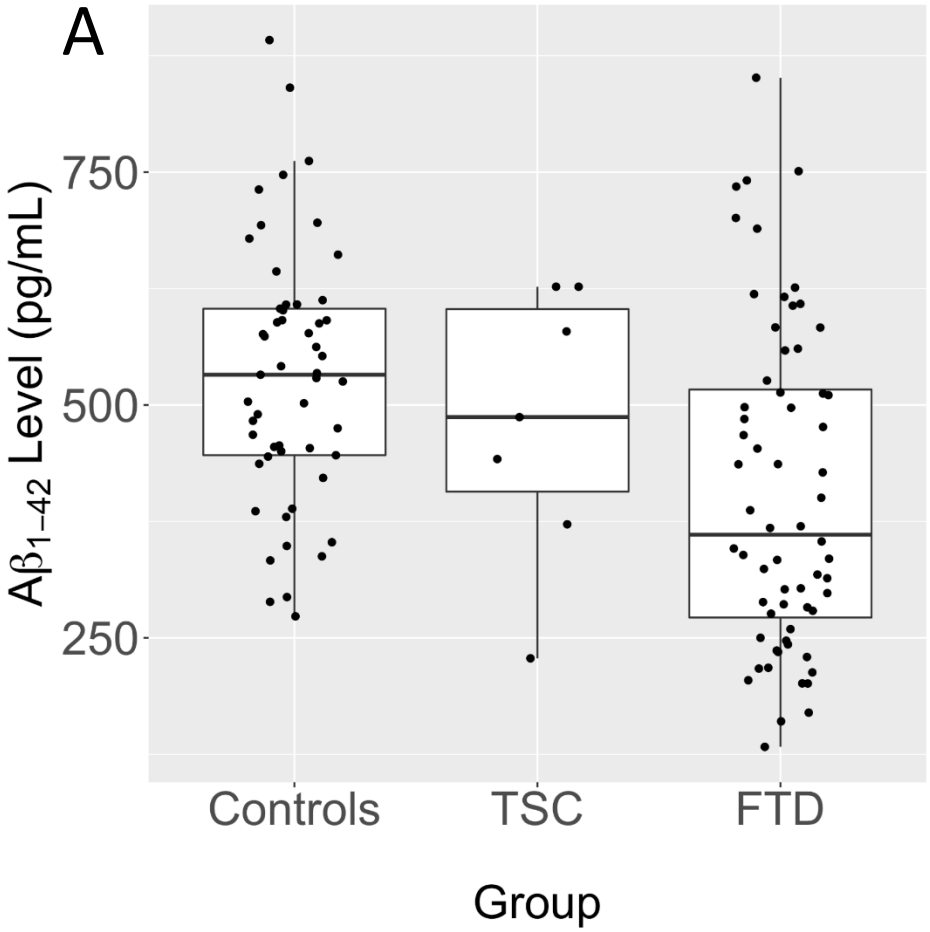

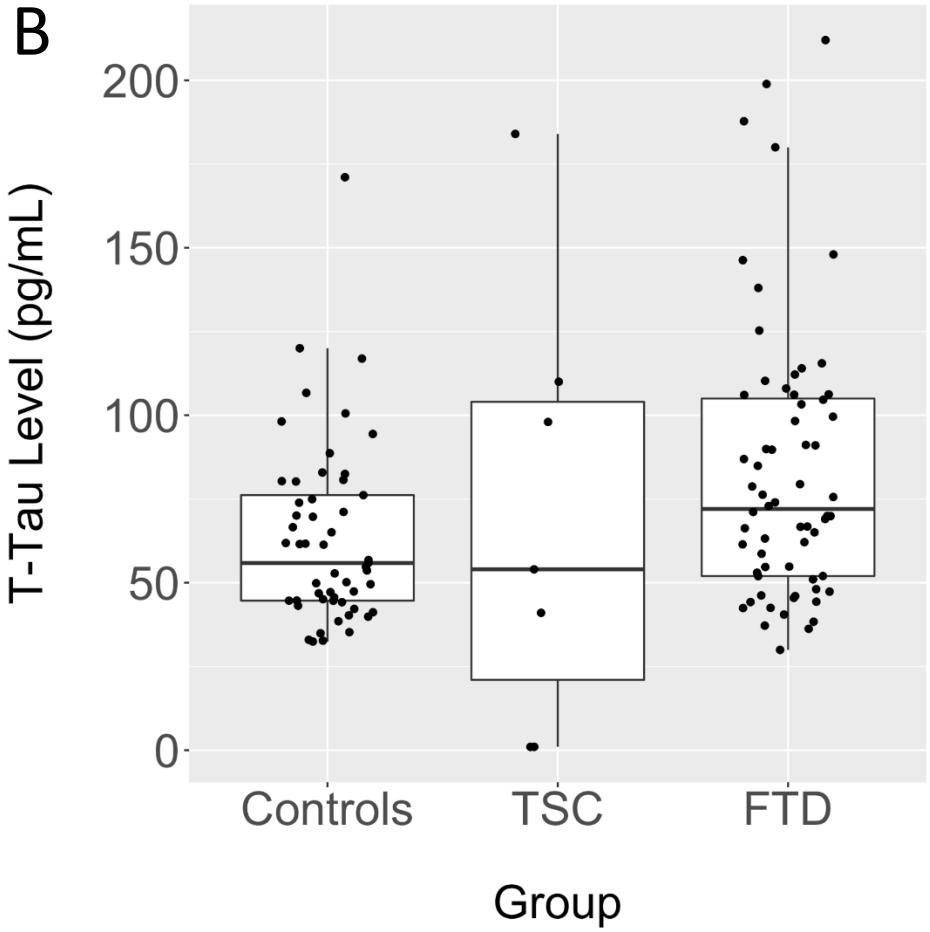

Department of Neurology
Duke University School of Medicine

Findings in adults diagnosed with TSC

- TAND symptoms vary
- TAND and FTD symptoms significantly overlap
- Imaging suggests deposition in specific areas of the brain that may explain cognitive symptoms
- Elevated CSF p-tau levels may be causing cognitive symptoms

Future direction

- Longitudinal studies with adults diagnosed with TSC is necessary to characterize the clinical trajectory
- Begin analyzing how imaging and fluid markers change over time in adults with TSC

Acknowledgements

- Bruce Miller, MD
- Aimee Kao, MD, PhD
- Adam Staffaroni, PhD
- Nick Olney, MD
- Carolina Alquezar-Burillo, PhD
- UCSF Memory and Aging Center
- Duke School of Medicine

Thank you

Andy.liu@duke.edu

https://www.dukehealth.org/find-doctors-physicians/andy-liu-md-ms

Department of Neurology
Duke University School of Medicine

References

- French, J. A., Lawson, J. A., Yapici, Z., Ikeda, H., Polster, T., Nabbout, R., … Franz, D. N. (2016). Adjunctive everolimus therapy for treatment-resistant focal-onset seizures associated with tuberous sclerosis (EXIST-3): a phase 3, randomised, double-blind, placebo-controlled study. *The Lancet*, *388*(10056), 2153–2163. https://doi.org/10.1016/S0140-6736(16)31419-2
- Kingswood, J. C., D'Augères, G. B., Belousova, E., Ferreira, J. C., Carter, T., Castellana, R., … Jansen, A. C. (2017). TuberOus SClerosis registry to increase disease Awareness (TOSCA) - Baseline data on 2093 patients. *Orphanet Journal of Rare Diseases*, *12*(1). https://doi.org/10.1186/s13023-016-0553-5
- Wu, J. Y., Salamon, N., Kirsch, H. E., Mantle, M. M., Nagarajan, S. S., Kurelowech, L., … Mathern, G. W. (2010). Noninvasive testing, early surgery, and seizure freedom in tuberous sclerosis complex. *Neurology*, *74*(5), 392–398. https://doi.org/10.1212/WNL.0b013e3181ce5d9e
- de Vries PJ, Whittemore VH, Leclezio L, et al. Tuberous sclerosis associated neuropsychiatric disorders (TAND) and the TAND checklist. *Pediatric neurology*. 2015;52(1):25-35. http://www.ncbi.nlm.nih.gov/pubmed/25532776. doi: 10.1016/j.pediatrneurol.2014.10.004.
- Olney N, Spina S, Miller B. Frontotemporal dementia. *Neurologic Clinics*. 2017;180(2):140-143. http://bjp.rcpsych.org/cgi/content/abstract/180/2/140. doi: 10.1192/bjp.180.2.140.
- Olney N, Alquezar C, Ramos E, et al. Linking tuberous sclerosis complex, excessive mTOR signaling, and age-related neurodegeneration: A new association between TSC1 mutation and frontotemporal dementia. *Acta Neuropathol*. 2017;134(5):813-816. https://search.proquest.com/docview/1951870885. doi: 10.1007/s00401-017-1764-0.
- Liu, A.J., Staffaroni A.M., Rojas, J.C., Olney, N.T., Alquezar-Burillo, C., Ljubenkov, P.A., La Joie, R., Fong, JC., Taylor, J., Karydas, B.A., Ramos, E.M., Coppola, G., Boxer, A.L., Rabinovici, G.D., Miller, B.L., Kao, A.W. Overlap in cognitive and behavioral features between adults with tuberous sclerosis and frontotemporal dementia. *JAMA Neurology*. Accepted October, 2019.